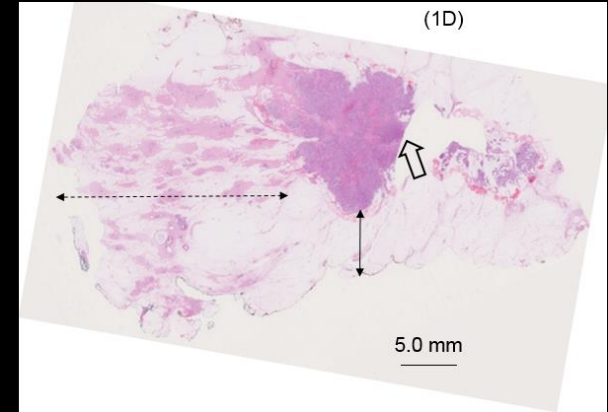
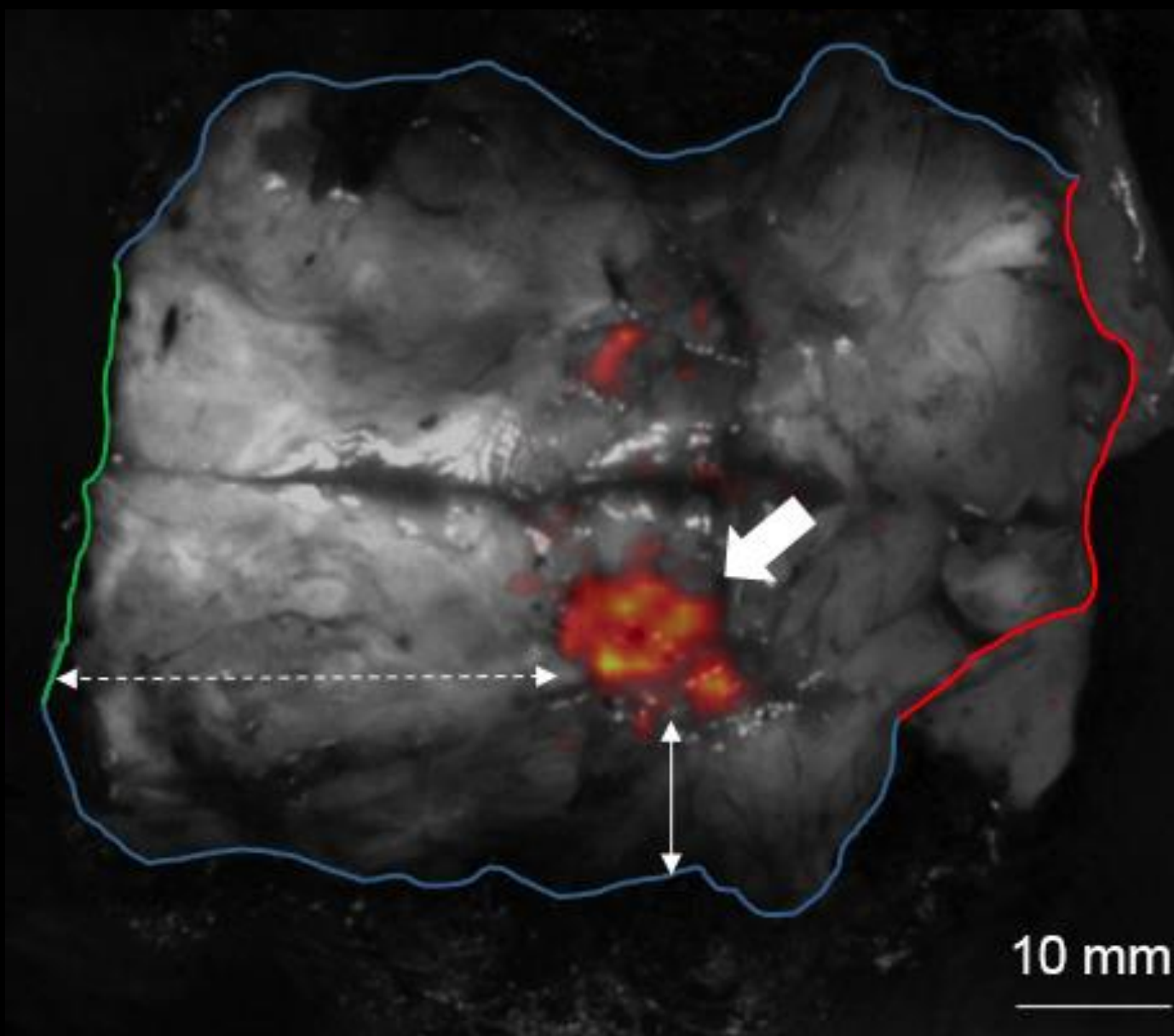





LightPath™ Images

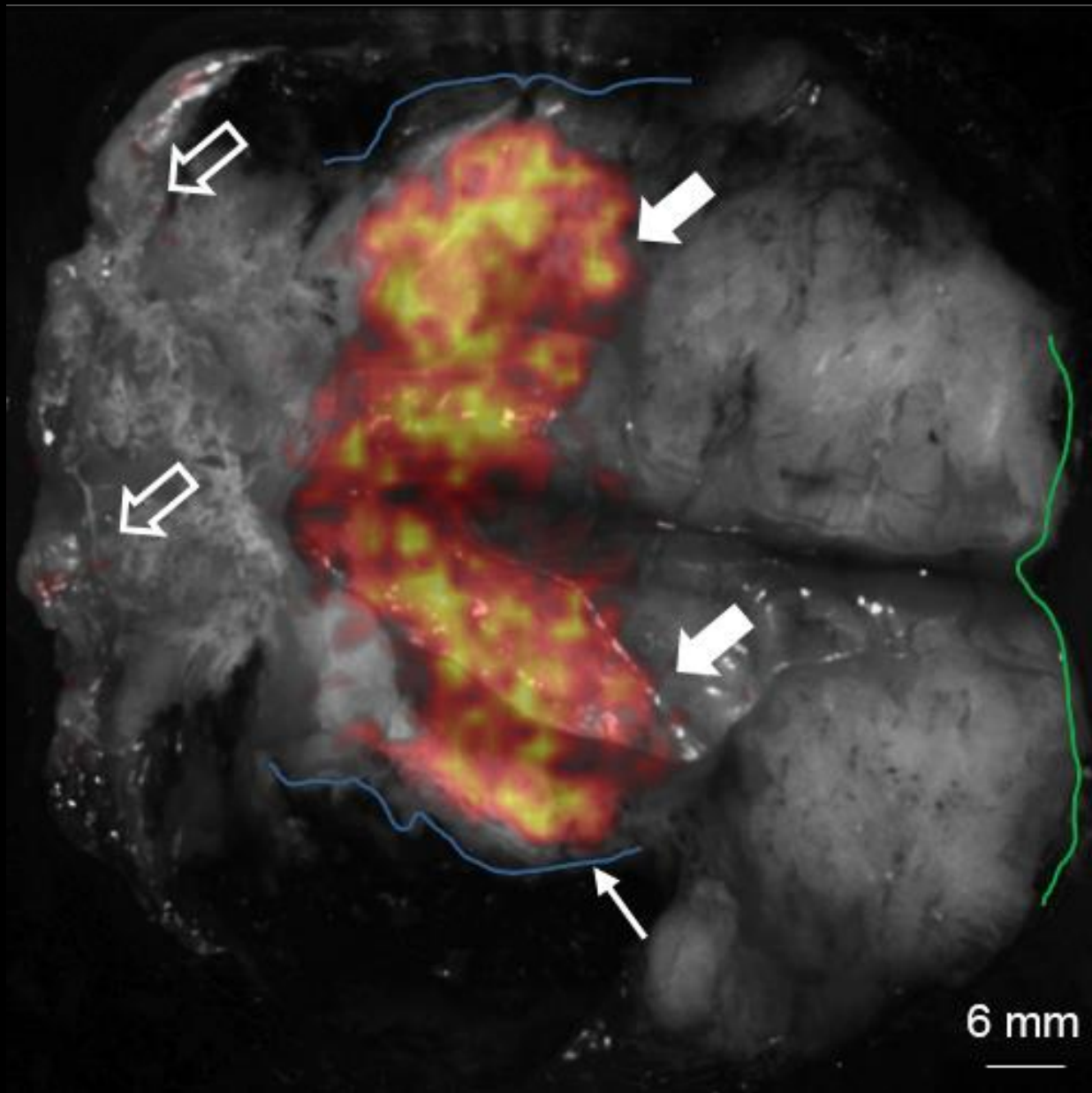
Intra-operative imaging using ground-breaking Cerenkov Luminescence
Imaging technology



Grade 3, ER+/HER2-, no special type (ductal) carcinoma admixed with high grade ductal carcinoma in situ (DCIS).



22 mm, Grade 2, ER+/HER2- invasive lobular carcinoma



Grootendorst MR et al, J Nucl Med. 2016

Grade 3, ER-/HER2- no special type (ductal) carcinoma.